

A COMPARATIVE STUDY OF MINIDOSE BUPIVACAINE-FENTANYL SPINAL ANESTHESIA WITH OR WITHOUT FASCIA ILIACA COMPARTMENT BLOCK FOR HIP SURGERIES – A PROSPECTIVE RANDOMIZED DOUBLE BLINDED STUDY

Selvi Annie Geeta¹, Loretta Raj. R², Ramya Gnanasekar², Mathana V²

Received : 04/10/2025
Received in revised form : 25/11/2025
Accepted : 12/12/2025

Keywords: Mini dose spinal anaesthesia, Hip Fracture, Fascia Iliaca Compartment Block, Ultrasound Guided block, Visual Analogue Scale.

Corresponding Author:
Dr Mathana V,
Email: mathanajerom@gmail.com

DOI: 10.47009/jamp.2025.7.6.164

Source of Support: Nil,
Conflict of Interest: None declared

Int J Acad Med Pharm
2025; 7 (6); 586-590



¹Associate Professor, Department of Anaesthesiology, Kanyakumari Govt Medical College Hospital, Asaripallam, Tamil Nadu, India.

²Assistant Professor, Department of Anaesthesiology, Kanyakumari Govt Medical College Hospital, Asaripallam, Tamil Nadu, India.

ABSTRACT

Background: Spinal anesthesia with conventional dose of bupivacaine for elderly people with multiple comorbidities, leads to hypotension. Intrathecal opioid as an adjuvant reduces local anesthetic dosage and when combined with fascia iliaca block provide a safe and effective form of anesthesia in hip surgeries. Results for successful anaesthesia for hip surgeries with Bupivacaine dose lower than 7.5 mg for intrathecal anaesthesia, with or without supplements like fentanyl are lacking. The purpose of this study is to compare intraoperative hemodynamic stability and postoperative analgesic efficacy in minidose spinal anesthesia with or without Fascia Iliaca Compartment Block. **Materials and Methods:** After Institutional Review Board approval and written informed consent, 40 patients of age group 50 to 80 years of both sex and ASA I to III undergoing hip surgeries were randomly allocated into two groups of 20 patients each. Group A received USG guided Fascia Iliaca Compartment Block (FICB) with 30 ml saline and unilateral spinal anesthesia with bupivacaine 5 mg plus fentanyl 25 µg, and Group B received USG guided FICB with 30 ml of 0.25 % bupivacaine and unilateral spinal anesthesia with bupivacaine 5mg plus fentanyl 25 µg. An Epidural catheter was placed in both groups as a precaution to provide rescue anesthesia if required. **Result:** Vasopressor requirement was nil in both groups. Total volume of fluids infused were comparable between two groups. Postoperative Visual Analogue Scale and total dose of rescue analgesic needed were significantly less ($P < 0.05$) in Group B which received minidose Bupivacaine fentanyl anesthesia with FICB. Duration of analgesia was also prolonged in Group B. **Conclusion:** “Minidose” of 5 mg bupivacaine in combination with 25µg fentanyl combined with Fascia Iliaca Compartment Block provides effective anesthesia for surgical repair of hip fracture in the elderly, nearly eliminating the need for vasopressor support of blood pressure and obviating the need for intravenous opioids in the postoperative period, thus aids in earlier rehabilitation and enhanced recovery.

INTRODUCTION

Hip fractures are increasing worldwide expecting an increase from 1.7 million in 1990 to 6.3 million in 2050. Hip fractures are extremely painful leading to physiological and psychological impact on patients which may delay operative intervention and prolong hospital stay. Regional anaesthesia techniques have revolutionized perioperative pain management providing effective analgesia while minimizing systemic opioid use and its associated side effects.

Nerve blocks also help in patient positioning, reduces the dosage of local anaesthetics administered intrathecally and thus avoiding side effects like spinal hypotension in sick frail patients, improves postoperative rehabilitation and reduces incidence of postoperative delirium. Fascia Iliaca Compartment Block (FICB), a relatively new regional anaesthesia technique selectively blocks the femoral, lateral femoral cutaneous, and obturator nerves offering reliable analgesia for various surgical procedures involving the hip and thigh, including hip fracture

repairs, hip arthroplasty, and thigh surgeries. It does not require the use of a nerve stimulator or mobilization of the limb, seems easier to perform in femur fracture surgeries, more reliable, away from neurovascular bundle providing prolonged duration of analgesia. FICB is performed by injecting a local anaesthetic agent into the fascia iliaca compartment which is a triangular-shaped space formed anteriorly by the inner aspect of the fascia iliaca, posteriorly by the outer aspect of the iliacus muscle, medially by the vertebral column and the upper part of the sacrum, and rostrally and laterally by the inner lip of the iliac crest to which the fascia is tightly attached. The use of ultrasound guidance enhances the accuracy and safety of the block, allowing for real-time visualization of needle placement and local anaesthetic spread. This technique offers several advantages over traditional analgesic approaches, such as systemic opioids or neuraxial anaesthesia, including improved pain control, reduced opioid consumption, decreased incidence of opioid-related side effects, and early mobilization of patients. Numerous studies have investigated the efficacy and safety of FICB, with growing evidence supporting its use in various clinical settings.

Aim: To compare the intraoperative hemodynamic stability and the postoperative analgesic efficacy in minidose spinal anaesthesia with or without Fascia Iliaca Compartmental Block.

Objectives

1. Intraoperative hemodynamics
2. Postoperative VAS score
3. Total opioid dosage consumed

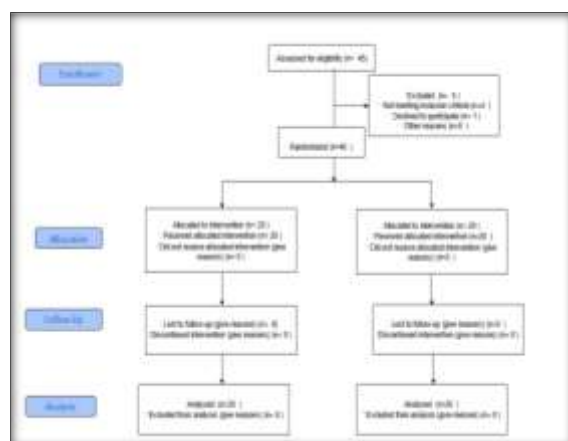
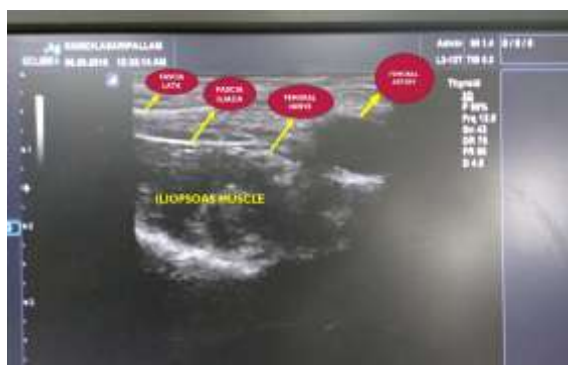Study Design: It is a prospective randomized double blinded study. Patients of age group 50-80 yrs posted for hip surgeries and who gave proper written informed consent were included for the study. ASA IV patients, prolonged surgery more than 180min, patients with coagulopathies, Cardiovascular instability, infection at site of block, patients allergic to opioids, significant peripheral neuropathy affecting lower extremity and with previous femoral bypass surgery in that limb to be operated are excluded from the study.

MATERIALS AND METHODS

After Institutional Review Board approval and written informed consent, 40 patients undergoing hip surgeries were selected. Sample size was calculated for a mean difference in duration of analgesia of 4 hrs with 80% power with an α Error of 0.05. Subjects were randomly assigned to either Group A or Group B, using a Sealed Envelope technique. Demographic information included age, height, weight and ASA classification. Baseline mean arterial pressure (MAP), systolic and diastolic blood pressure, heart rate (HR) was recorded. Using an Infra-Inguinal approach with the patient in the supine position, a high-frequency linear ultrasound transducer (6–14 MHz) was positioned transversely at the inguinal

crease to identify the femoral artery. The iliopsoas muscle and the overlying fascia iliaca were visualized, with the femoral nerve appearing as a hyperechoic structure located lateral to the femoral artery between the iliopsoas muscle and the fascia iliaca. The probe was gently angled cranially and caudally to optimize visualization of the femoral nerve and the fascia iliaca. Lateral movement of the transducer allowed identification of the sartorius muscle and the anterior superior iliac spine.

Following aseptic skin preparation and infiltration of local anaesthetic, a 100-mm blunt-tipped needle was advanced using an in-plane ultrasound-guided technique. The needle tip was positioned beneath the fascia iliaca at approximately the lateral one-third of the line joining the anterior superior iliac spine and the pubic tubercle. After confirming appropriate needle placement, in Group A 30 ml of saline was given. In Group B 30 mL of 0.25% bupivacaine was administered. Successful placement was confirmed by ultrasound visualization of separation of the fascia iliaca from the iliopsoas muscle, with spread of local anaesthetic extending medially toward the femoral nerve and laterally toward the iliac crest. Pain assessment was done using Visual Analogue Scale after the block. Sensory function was assessed for all 3 nerves (femoral, obturator, and LFC nerves) by using pinprick sensation. Sensory function was assessed in the areas being investigated by asking the subjects to report if they felt sensation (P = present) or did not feel sensation (A = absent). 30 minutes later patient positioned laterally with operative limb in dependant position an Epidural catheter was fixed at L2 – L3 interspace and spinal anaesthesia (hemi spinal) was performed with 0.5% Bupivacaine 5 mg + 25 μ g fentanyl in L3, L4 interspace in both groups. HR, MAP, SBP, DBP were measured at 15-minute interval up to 90 minutes or end of surgery whichever is earlier using Philips continuous multipara monitor. Hypotension defined as a systolic pressure of < 90 mmHg or a 25% decrease in mean arterial pressure from baseline and treated with intravenous ephedrine boluses 6mg to a maximum of 50 mg. Postoperatively, VAS score was assessed and recorded at hourly intervals up to 12hrs after surgery. Total dose of rescue analgesia (Inj. Tramadol 100mg IM) administered was recorded. Any side effects like headache, pruritus, nausea, vomiting, shivering, respiratory depression noted.

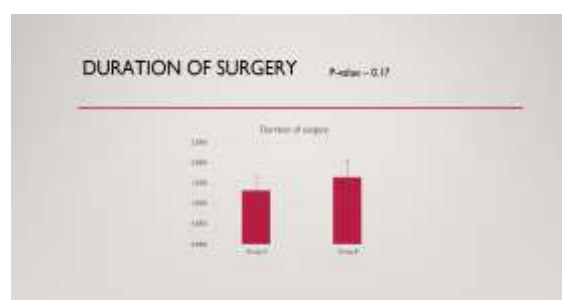
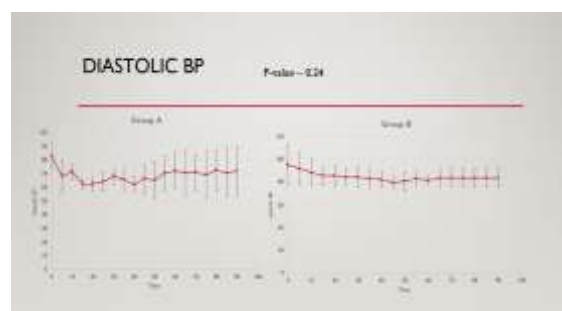
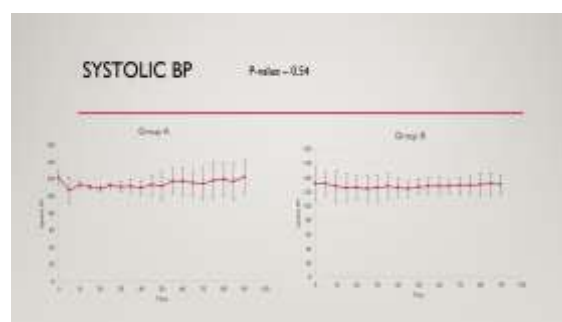
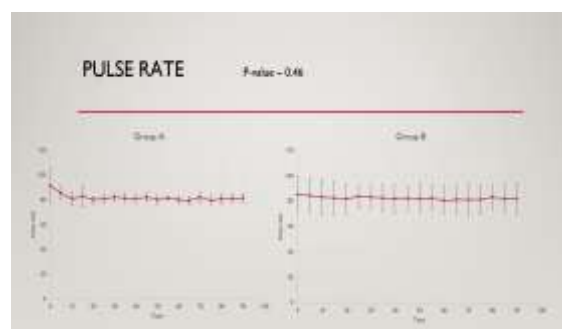
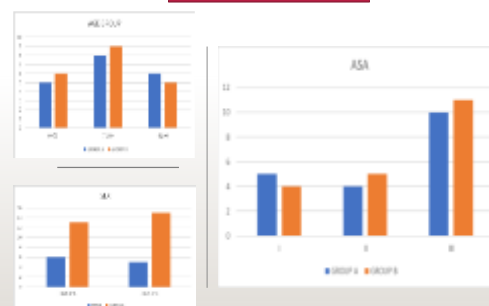

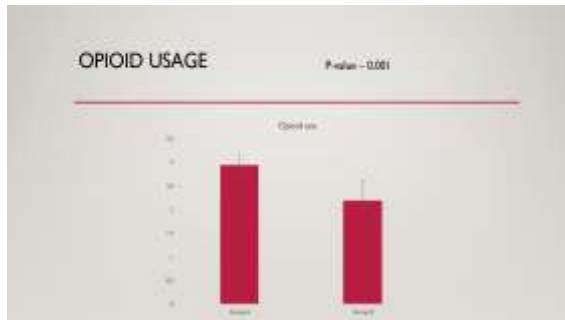

Statistical Analysis: The data obtained was subjected to statistical analysis using Student t test and Chi-Square test. The Statistical Software SPSS 23.0 were used for the analysis of the data and Microsoft word and Excel have been used to generate graphs, tables etc. The value of $P < 0.05$ was considered significant.

RESULTS

There were 20 patients in each of the two groups. There were no differences between the demographic characteristics of the two groups. Level of sensory block achieved after unilateral spinal anesthesia was T10 – T12 and was comparable. Intraoperative hemodynamics, vasopressor usage and total fluids infused were comparable between two groups. Duration of surgery (1.52 hours and 1.34 hours) was comparable between two groups and statistically insignificant ($p = 0.17$). Duration of analgesia was prolonged in Group B and found to be statistically significant ($P < 0.001$). The side effect profile was also comparable with slightly higher incidence of pruritus in both the groups which was again a non-significant entity.

DEMOGRAPHICS





VAS scores

Post operative duration	Group	VAS score (mean ± SD)	P-value
1 hour	Group 1	0.0 ± 0.0	0
	Group 2	0.0 ± 0.0	
2 hours	Group 1	1.2 ± 1.9	0.01
	Group 2	0.0 ± 0.0	
3 hours	Group 1	2.3 ± 2.1	0.001
	Group 2	0.0 ± 0.0	
4 hours	Group 1	2.7 ± 2.1	0.14*
	Group 2	1.3 ± 2.0	

* - not significant

DISCUSSION

This study was based on National Hip Fracture Database: Anaesthesia Sprint Audit of Practice 2014 standards

- Standard 1: Patients should be anaesthetised by a consultant or specialist with similar clinical experience.
- Standard 2: Spinal/epidural anaesthesia should be considered for all patients
- Standard 3: Spinal anaesthetics should be administered using hyperbaric bupivacaine

(<10mg) with the patient positioned laterally (bad hip down)

- Standard 4: Co-administration of intrathecal opioids should be restricted to fentanyl
- Standard 5: If sedation is required this should be midazolam or propofol
- Standard 9: Consider intraoperative nerve blocks for all patients undergoing surgery
- Standard 10: Neuraxial and general anaesthesia should not be combined
- Standard 11: Hypotension should be avoided

We combined Fascia Iliaca Compartment Block with small dose of local anaesthetic for SAB. The minimum effective dose of hyperbaric bupivacaine is 4mg. Here we used 5mg to avoid spinal anaesthesia induced adverse effects. We combined SAB with FICB since it effectively provides analgesia for positioning for spinal anaesthesia to patients in hip and proximal femur surgeries and also many studies have proven its efficacy in prolonging the duration of analgesia. In our study we found it comfortable for patient positioning, decrease in opioid usage and prolonging the duration of analgesia thereby improving patient mobilization. ASA IV patients and prolonged surgeries were excluded, limiting applicability to more critically ill elderly patients.

CONCLUSION

“Minidose” of 5 mg bupivacaine with 25µg fentanyl combined with Fascia Iliaca Compartment Block provides effective anaesthesia for surgical repair of hip fracture in the elderly, nearly eliminating the need for vasopressor support of blood pressure and obviating the need for intravenous opioids in the postoperative period, thus aids in earlier rehabilitation and enhanced recovery.

REFERENCES

1. Association of Anaesthetists of Great Britain and Ireland. Management of Proximal Femoral Fractures 2011. Anaesthesia 2012; 67: 85–98.
2. The management of hip fracture in adults. Clinical guideline CG124. NICE, London 2011 (<http://guidance.nice.org.uk/CG124>).
3. Anaesthesiology 2000; 92:6–10 © 2000 American Society of Anaesthesiologists, Inc. Lippincott Williams & Wilkins, Inc. Minidose Bupivacaine–Fentanyl Spinal Anaesthesia for Surgical Repair of Hip Fracture in the Aged Bruce Ben-David, M.D.* Roman Frankel, M.D., * Tatianna Arzumov, M.D., * Yuri Marchevsky, M.D., * Gershon Volpin, M.D.†
4. Imbelloni LE, Beato L, Cordeiro JA. Unilateral spinal anaesthesia with low 0.5% hyperbaric bupivacaine dose. Rev Bras Anesthesiol. 2004; 54:700–6. [PubMed]
5. Frequency of hypotension during conventional or asymmetric hyperbaric spinal block. Casati A, Fanelli G, Aldegheri G, Colnaghi E, Casaletti E, Cedrati V, Torri G Reg Anesth Pain Med. 1999 May-Jun; 24(3):214–9. [PubMed] [Ref list]
6. Indian J Orthop. 2018 Mar-Apr; 52(2): 147–153. Doi: 10.4103/ortho.IJOrtho_298_16 PMID: PMC5858208 PMID: 29576642 Comparative Study for Evaluating Efficacy of Fascia Iliaca Compartment Block for Alleviating Pain of Positioning for Spinal Anaesthesia in Patients with Hip and Proximal Femur Fractures Nirav Jentilal Kacha, Chetna A Jadeja, Pooja J Patel, Harshda B Chaudhari, Jatin R Jivani, and

Vandana S Pithadia Department of Anaesthesiology, P. D. U.
Medical College, Rajkot, Gujarat, India

7. Incidence and risk factors for side effects of spinal anaesthesia. Carpenter RL, Caplan RA, Brown DL,

Stephenson C, Wu R Anaesthesiology. 1992 Jun; 76(6):906-16.